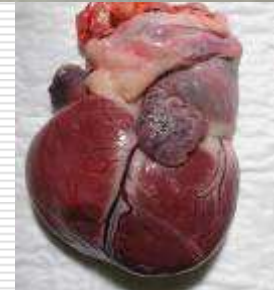


EKG Quiz

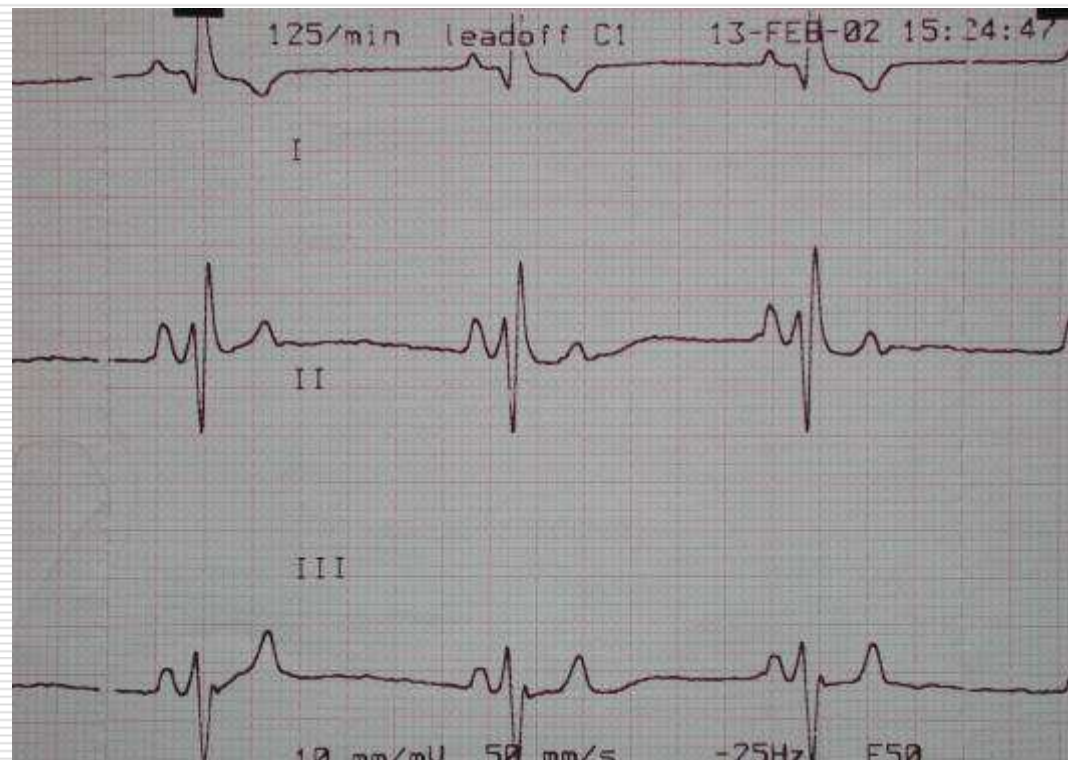
in Small Animal Practice

Jørgen Koch
Head of Cardio-pulmonary Service
DVM ph.d
Department of Small Animal Diseases
LIFE, University of Copenhagen
jko@life.ku.dk

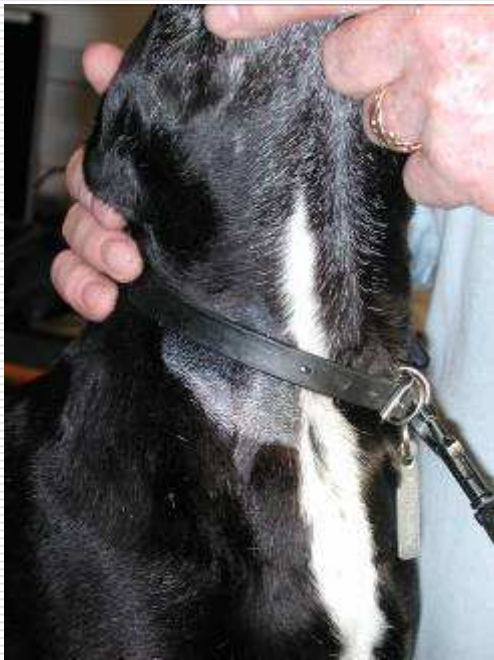

1. Caesar, labrador, male, 4 years-old

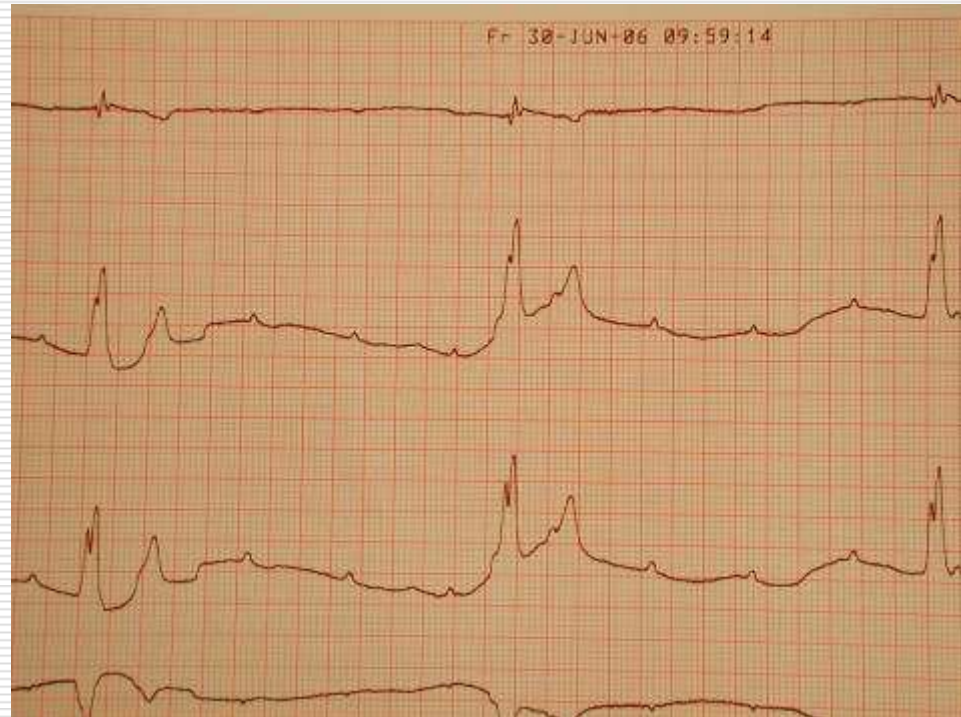
- Referred with a history of episodes with tachycardia and syncope



2. Mix breed, male dog, 9 years-old with syncope and bradycardia

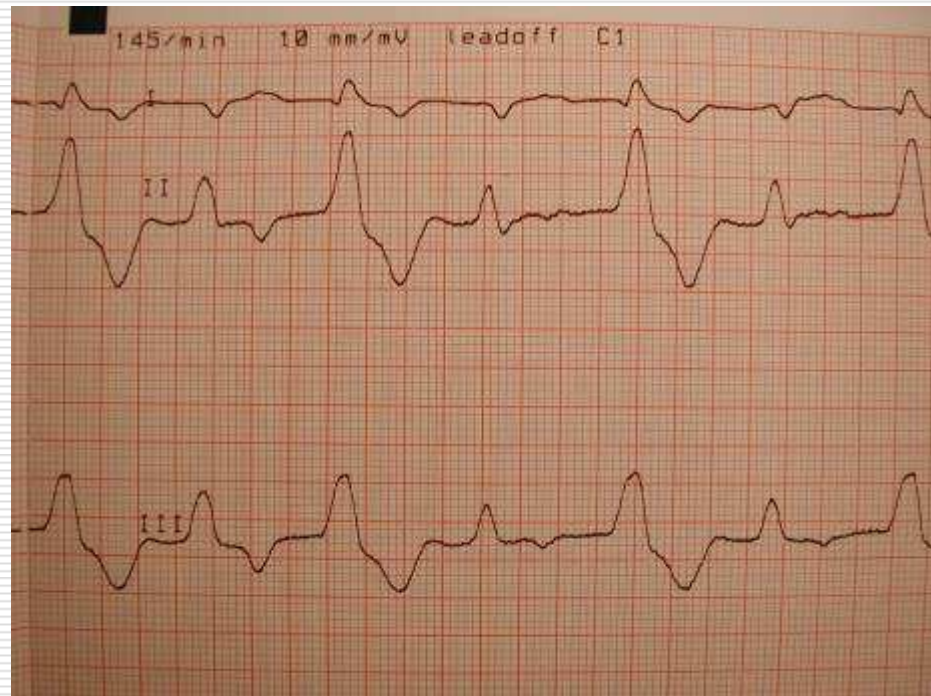


Jugular vene distended



3. Domestic shorthair cat, male, 5 years-old with dysuria

- Anamnesis
 - Vocalization and pain for more than a day
 - Tried to urinate several times
- Physical examination
 - Moribund
 - Large bladder
 - Arrhythmias



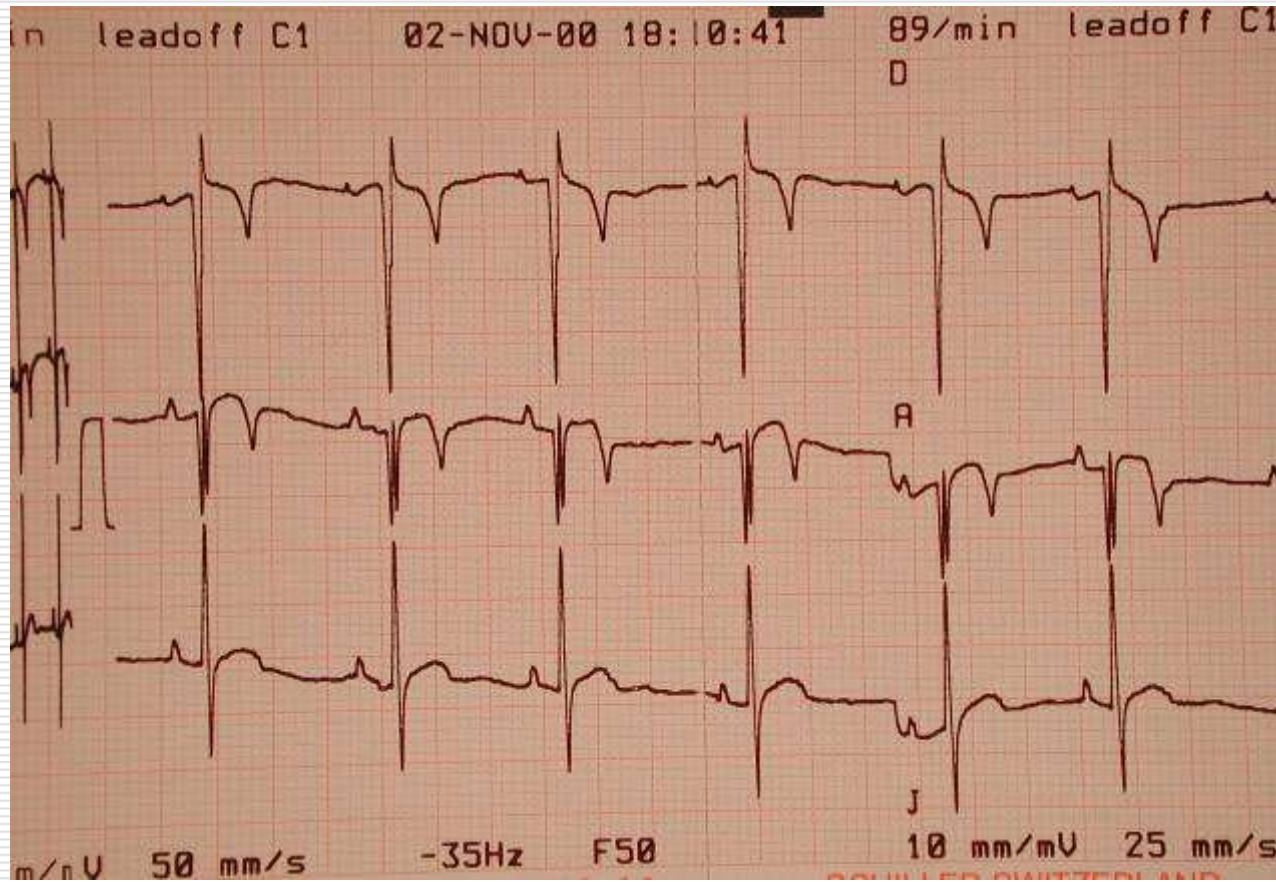
4. Westie "Anton"

- Male, 2 years-old
- History
 - Exercise intolerant
- PE
 - Cyanotic
 - HR 90/min
 - No murmur
 - PCV – 65%!

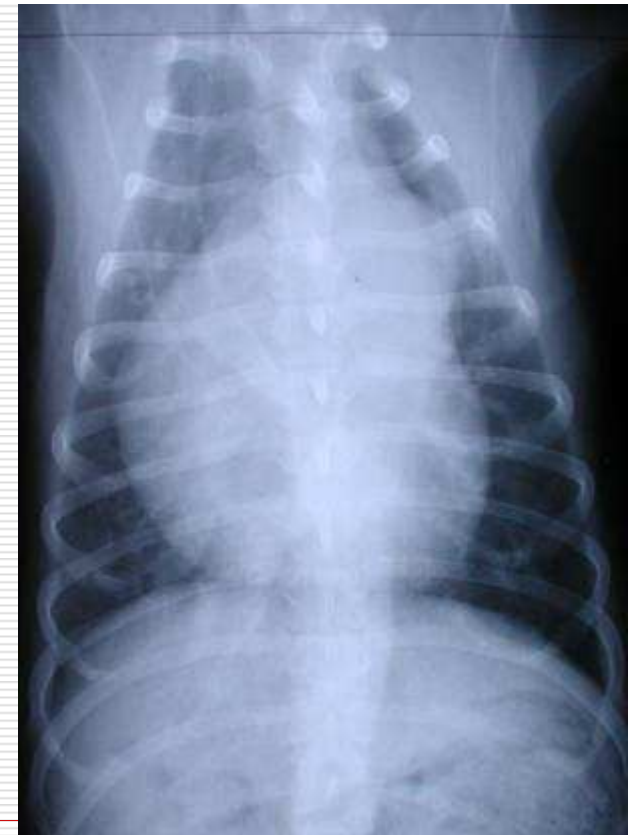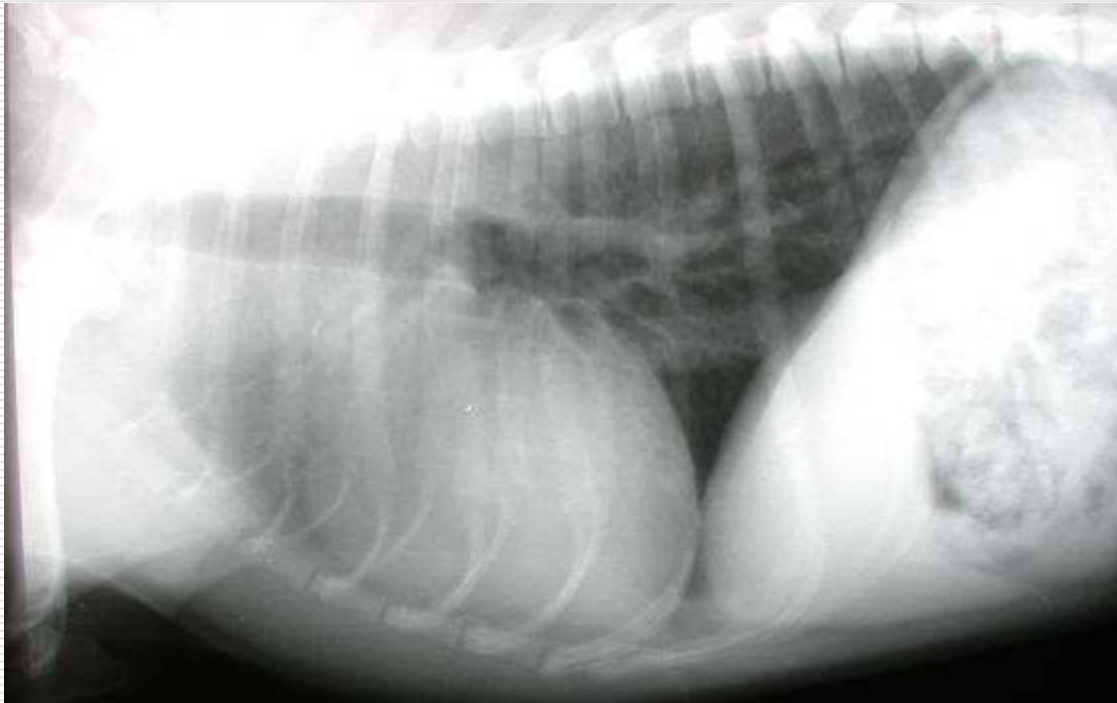


Electrocardiogram

EKG

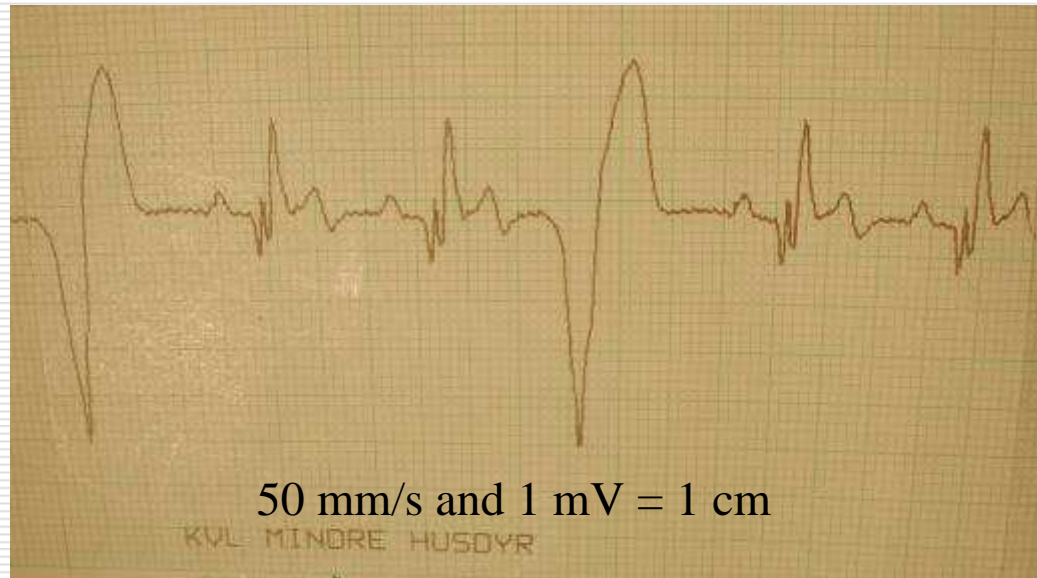


X-ray

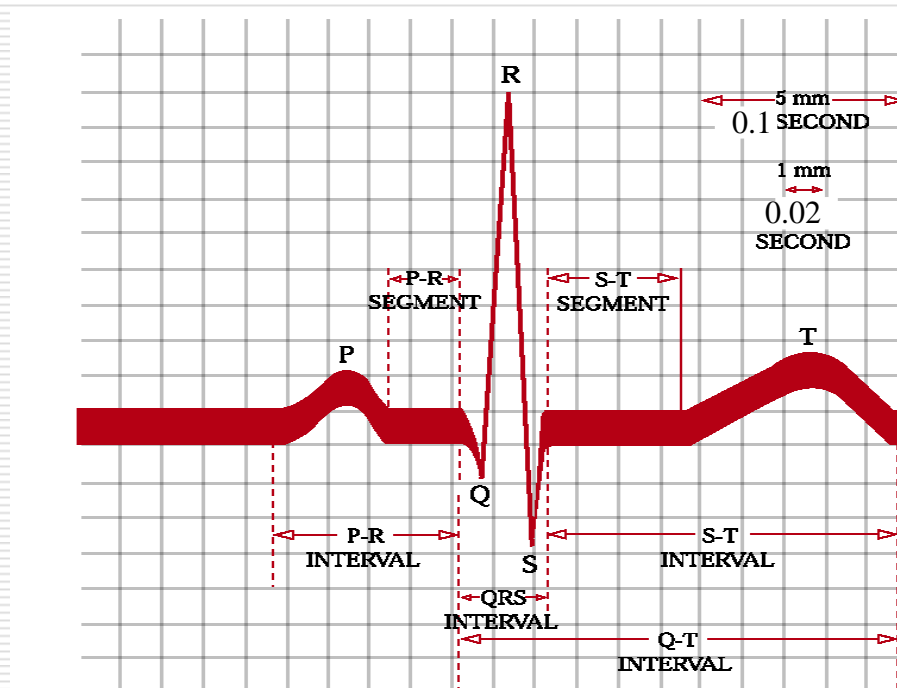


5. EKG quiz

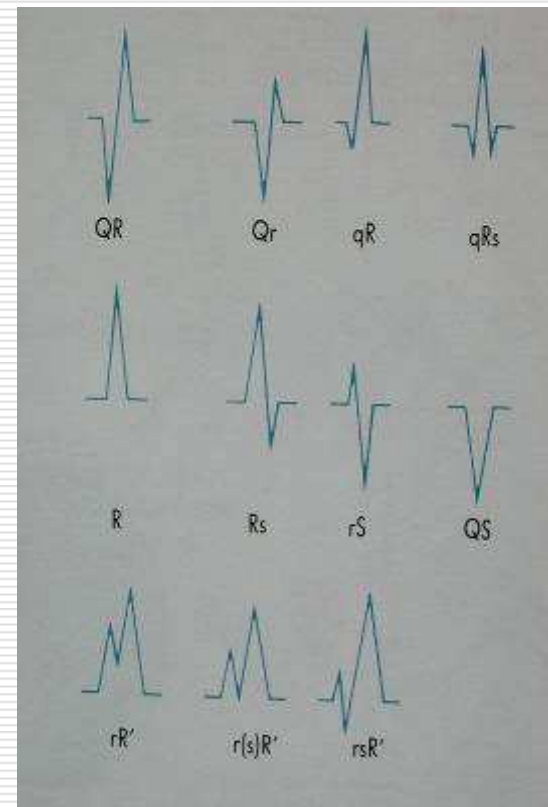
- ❑ Border collie 5 years-old female with fatigue and weak pulse with deficits



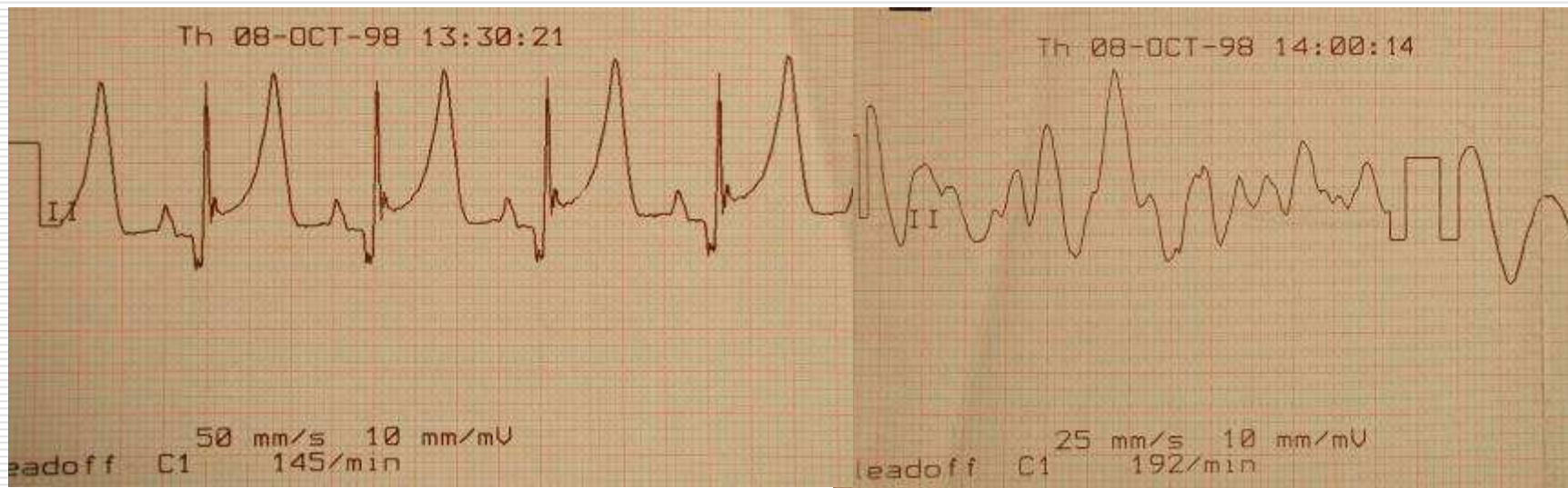
Recordings conventions and waveform nomenclature



50 mm/s; 1 cm = 1mV



6. Pelle, Kleiner Münster Länder, male, 4 years-old presenting with syncope



Tricuspid murmur and increased D-dimer

EKG assessment and treatment?
